

# The next frontier for recovering endangered huemul (*Hippocamelus bisulcus*): how to avoid recurrent misdiagnoses of health status and risks

Werner T. Flueck<sup>A,B,C,F</sup> and Jo Anne M. Smith-Flueck<sup>D,E</sup>

<sup>A</sup>National Council of Scientific and Technological Research (CONICET), Rivadavia 1917, 1033 Buenos Aires, Argentina.

<sup>B</sup>Argentine National Park Administration, Bariloche, Argentina.

<sup>C</sup>Swiss Tropical and Public Health Institute, University Basel, Socinstrasse 57, 4051 Basel, Switzerland.

<sup>D</sup>Laboratorio de Teriogenología 'Dr Héctor H. Morello', Facultad de Ciencias Agrarias, Universidad Nacional del Comahue, Cinco Saltos, Argentina.

<sup>E</sup>DeerLab, Rolando 699, 8400 Bariloche, Argentina.

<sup>F</sup>Corresponding author. Email: wtf@deerlab.org

## Abstract

**Context.** The currently remaining 350–500 huemuls in Argentina are not recovering. We evaluated live huemuls, along with animals that died soon after confinement, or those that had died recently. Although information on the health status is highly valuable, repeated misdiagnoses of the health status indicate a need for other strategies.

**Aims.** Discrepancies between clinical and postmortem diagnoses are critical for improving subsequent management decisions.

**Methods.** Initial clinical interpretations and risk assessments were reinterpreted on the basis of necropsies and other data.

**Results.** Two debilitated huemul individuals examined by veterinarians died soon afterwards, supposedly one being intoxicated and one being without lesions. Necropsies showed osteopathology and fluorosis (fluorine concentrations of 2209 and 2979 mg/kg). Another male was tied up, with authorities and veterinarians arriving the next day. After being sedated, and judged healthy, the animal was translocated. Because there was no reversal, this animal died 22 h post-capture. Exhumation showed severe osteopathology. Elsewhere, huemuls were considered adequate in selenium because values below the detection limit were excluded. However, when all values were included, 75% of the animals were selenium-deficient; this population had numerous cases of osteopathology. Recently, specialists went to Torres del Paine Park suspecting caseous lymphadenitis, reporting of which has been obligatory since 1937. However, many cases documented in 1999–2007 have not elicited responses since that time by health professionals. Selenium deficiency negatively affects antibody responses against caseous lymphadenitis. One province had denied huemul capture (2012 and 2013) on recommendation of scientific advisors. Because of the right for transparency, it was found out in 2016 that authorities had requested advice from only one veterinarian who assessed that darting was too risky. Another 2016 project proposed to dart the first huemul in Argentina. Two weeks earlier, that same team was called to rescue a tied-up huemul; the team opted not to involve a laboratory with drugs and radios that was only 1 h away. This huemul died and was left in the woods. Finally, the first huemul enclosure in Argentina was proposed (1995), but the permission was denied. Again, in 2000, the first huemul centre with private funding secured for 30 years was proposed. However, the Regional Delegation for Patagonian National Parks prevented aerial surveys, and advised not to provide a permit for the centre.

**Conclusions.** Future assessments should consider osteopathology. Risk assessments should be transparent and based on assessment by multiple qualified professionals.

**Implications.** Clinical misdiagnoses may reduce life expectancy, in contrast to taking individuals to enclosures, which would also allow valuable reintroductions. Not permitting captures, censuses and enclosures has resulted in unwarranted delays in conservation progress.

**Additional keywords:** breeding centre, conservation biology, pathology, recovery.

Received 8 November 2018, accepted 17 September 2019, published online 6 May 2020

## Introduction

In Argentina, only 350–500 individuals of Patagonian huemul deer (*Hippocamelus bisulcus*) are remaining, and fragmented into some 50 subpopulations along 1850 km of Andean mountains (IUCN 2001; Fig. 1). No groups are documented to be recovering; rather, the process of local extinctions is continuing (Flueck and Smith-Flueck 2006). The difficulty in accessing remote locations of the extant huemul has hindered research; thus, in Argentina, the first female was captured and radio-marked only in 2016, with six more that were being marked in 2017 in another population (Flueck and Smith-Flueck 2017). Thus far, evaluations of intact animals, besides these seven marked deer, have been based on a few rare animals that died soon after confinement, or on those that had died recently. Although few, these examined huemul individuals could serve as highly valuable case studies to help understand important issues regarding the ecology and sanitary status, and as sources of biological tissues, particularly viable gametes.

Instead, a high incidence of misdiagnosis of the health condition raises the question about what strategies to consider

so as to minimise these diagnostic errors, and consequential inappropriate treatments, and, thereby, reduce any unfavourable consequences. Here, we present several cases involving misdiagnoses, with our corresponding alternative interpretations. We also address assessments of methods and risks resulting in decisions with harmful consequences for conservation measures.

## Materials and methods

Several huemul cases were diagnosed *in vivo*, some of which were later also subjected to necropsies, along with others that had recently died. Remains were frequently buried after the initial examinations, but in some cases the huemul carcasses were buried without prior necropsies. After exhuming each carcass, a necropsy was performed using techniques of Salwasser and Jessup (1978) and Wobeser and Spraker (1980), and included inspections for macroscopic lesions. Pathological changes were evaluated according to Davis and Anderson (1971), Davis *et al.* (1981) and Jones *et al.* (1997). Determination of fluorine concentrations was performed according to Flueck and Smith-Flueck (2013). The initial reports of *in vivo* and postmortem diagnoses were then analysed with regards to our necropsy and analytical results. Last, other assessments, which are used to make decisions on conservation measures, were evaluated.

## Results and discussion

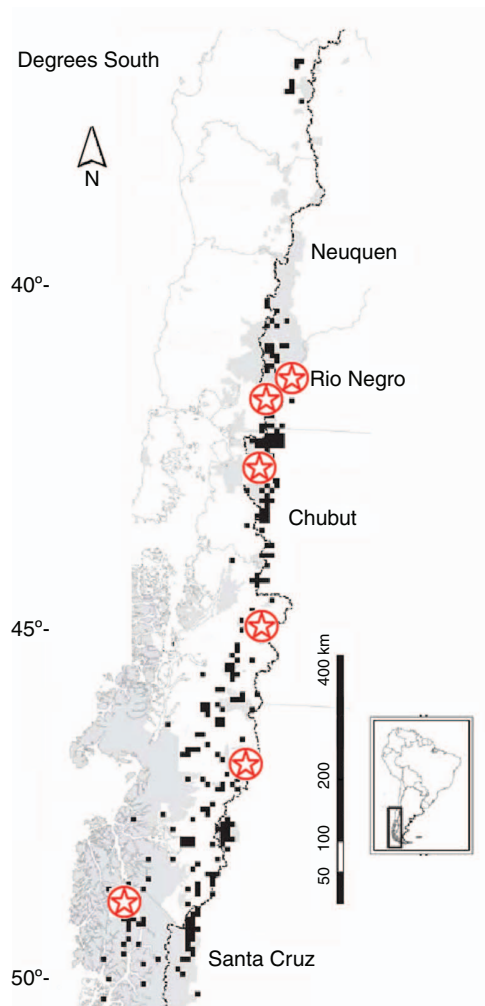
### *Alternative diagnoses of health condition*

#### *Case 1*


In the National Park Los Alerces (NPLA), a pregnant female found in a delicate state (depressed and reluctant to move) was taken to a pen for veterinary supervision, where she died soon after. On the basis of a necropsy and tissue analysis (Chang Reissig *et al.* 2015), it was reported that she was intoxicated and that it is likely that she died from consumption of toxic locoweed (*Astragalus pehuenches*).

However, a subsequent analyses after exhuming the remains also showed clear signs of osteopathological processes in the mandibular and maxillary bones, and, moreover, columnar and appendicular lesions (Fig. 2a–c). Cases of equivalent pathology in huemul have been documented in relation to selenium (Se) deficiency in another population (Flueck 2015). Also, several histological and clinical-chemistry findings on this female were compatible with Se deficiency. Last, at encounter, the female was reluctant to walk, and remained motionless with an arched back (Fig. 2d), which is also typical of Se deficiency (Hebert and Cowan 1971). Additionally, bone fluorine concentrations in this female reached 2209 mg/kg (Izquierdo *et al.* 2018), which explains the depressed state (rather than stemming from *A. pehuenches*), and is supported by the high fluorine concentrations in volcanic ashes deposited from the 2008 eruption of the Chaitén volcano. Fluorine is a neurotoxin, as classified in the Lancet by Grandjean and Landrigan (2014). In humans, it results in a lowered IQ, behavioural deficits, nervous disorders and memory disruption. Abundant animal studies have demonstrated adverse effects of fluorine on the brain.

Regarding *Astragalus pehuenches*, despite the huge number of livestock in Argentina and South America, intoxication was



**Fig. 1.** The various subpopulations of huemul known to occur between 37°S and 54°S (■), and those with documented cases of osteopathology (☆).



**Fig. 2.** Osteopathology in mandibular and maxillary bones (*a–c*); at encounter, the debilitated female was reluctant to walk, and remained motionless with an arched back typical also for selenium deficiency (*d*; courtesy of Fernando Corvalán).

not identified in any area until 2000, when it was found in sheep (Robles *et al.* 2000; Aitken 2007). More importantly, *A. pehuenches* does not even occur in the area of the huemul in this case (Robles *et al.* 2000; Martínez *et al.* 2014), which explains its absence in rumen and faeces contents of this huemul individual (Chang Reissig *et al.* 2015). Moreover, there are millions of mule deer (*Odocoileus hemionus*) in North America, and a review has shown that locoweeds are well distributed, with damage caused to livestock totalling millions of US\$, yet there are no reports of spontaneous locoweed poisoning among these deer (Stegelmeier *et al.* 2005). Also, the expression of clinical symptoms in deer is quite different from that in other species (i.e. sheep, cattle, horses; Stegelmeier *et al.* 2005).

### Case 2

A huemul buck individual in the NPLA region was found in a delicate state and taken to a pen for supervision, where he died soon after, in August 2013. The veterinarians performing the necropsy did not report any health problems except a haematoma on the thorax; no report was completed, only the head and skin were preserved, and the rest was buried. The young male was filmed 1 day pre-mortem together with an older male, but was found debilitated next to road the following day. The haematoma was interpreted as having been caused possibly by a vehicle collision.

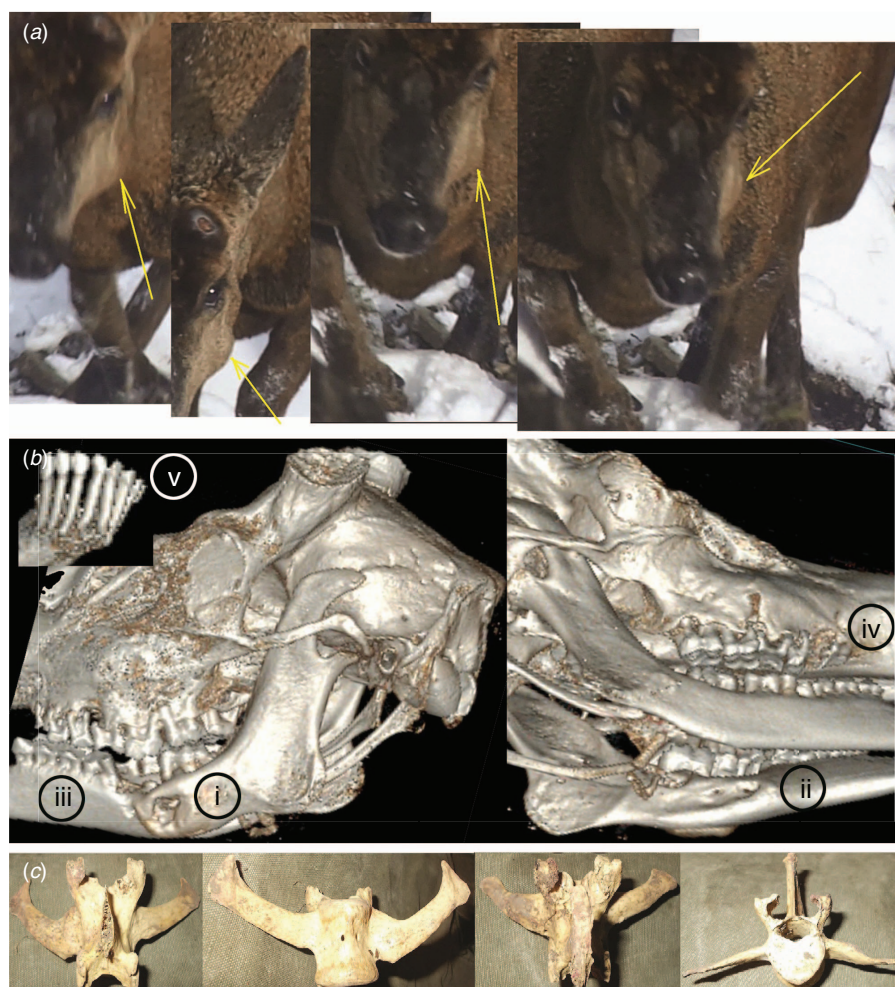
However, on the basis of a subsequent analyses after exhumation 2 years later, the animal in this case was also shown to have clear signs of osteopathological processes in the column, and *in vivo* photos clearly showed a swelling on the left-mandibular side (Fig. 3). Moreover, this deer also had

very high bone fluorine concentrations, reaching even 2979 mg/kg (Izquierdo *et al.* 2018). Although death might have resulted from an impact with a vehicle, the severe skeletal clinical pathologies went unnoticed, and, yet, these must have played a mayor role in the health status of the animal. Additionally, fluorosis was not considered, although volcanic ashes are still present today. Whereas the fluorosis may have affected the behaviour and metabolism, the observed bone asymmetries, healed fractures, exostosis and deformed growth patterns (Fig. 3) are also compatible with trace-mineral deficiencies, such as that of Se. Last, 6 years post-mortem, it was finally possible to analyse the frozen head by using computed tomography. The *in vivo* swelling resulted from the mandible being severely affected on both sides, exhibiting exostosis with simultaneous bone resorption, including perforations. Bone resorption also resulted in mandibular and maxillary tooth loss, exposed roots of molars, and complete exposure of all incisive teeth toots (Fig. 3*a–e*). The severity of these lesions undoubtedly reduced feeding capacity due to agony, and thereby reduced the physical condition, which might have contributed to the death.

### Case 3

One evening, a huemul buck was cornered by dogs inside a fenced area alongside the El Manso River, province of Rio Negro. The local farmer deterred the dogs and then roped and attached the buck to a fence post (Fig. 4*a–e*). Authorities were contacted immediately, but did not arrive until the afternoon of the next day. After sedation, the animal was evaluated by veterinarians, being considered uninjured and healthy, and thus was translocated some 6.5 km to another site for





**Fig. 3.** (a) Photos *in vivo* show an affected left mandibula (arrows). (b) Left mandible with severe exostosis on buccal side and bone resorption including perforations on buccal (i) and lingual side (ii); mandibular (iii) and maxillary (iv) tooth loss and exposed roots of molars; complete exposure of all incisive teeth roots (v). (c) Aberrant growth and asymmetry of vertebra.

release. However, he died there shortly after, not recovering from the drug after >22 h post-capture (they had no reversal). Although the carcass was left at the site of death and covered with some branches, it was later removed by others and buried elsewhere to prevent scavenging. Three and a half months after the buck's burial, a permit was finally received for its exhumation. The general body condition was good, on the basis of the fat reserves (early autumn). But in contrast to the initial veterinarian report (Chehebar 2016), the subsequent necropsy of the exhumed carcass showed skeletal health issues, being particularly severe in the mandible and maxilla.

Although the initial diagnosis stated that the huemul did not have any lesions and was in good condition, several pathological anomalies went undetected by veterinarians (Barbato 2016, p. 70). These lesions included asymmetrically grown vertebrae, osteodystrophy and fenestration of very thin scapula, osteolysis and deformation of the mandibula, disappearance of several teeth alveoli, molars broken into several pieces or misaligned, very thin-walled maxillae with dental root exposure, or porous and recessed bone (Fig. 4*f-k*). In fact, regarding animal welfare, such severe lesions are severe


enough to warrant urgently taking the sick animal to a rehabilitation centre (Flueck 2018; Lopez Alfonsin 2019; Lopez Alfonsin and Sol Bucetto 2019).

#### Case 4


A female in Los Glaciares National Park, immobilised to be marked in April 2016, was evaluated by a team of veterinarians (APN 2016*a*). The animal was considered healthy and apt for release. However, photos of the animal taken before capture, during immobilisation, and, later, after her release, indicate that she had a swelling on the left-mandibular side (Fig. 5). These types of swellings frequently indicate underlying processes such as bone disease or infections, and justify taking the animal to a rehabilitation centre. No reports are, yet, available regarding follow-up monitoring of this individual.

#### Case 5

A huemul subpopulation in Chile was recently evaluated for the status of the trace-mineral Se. Although huemul



**Fig. 4.** The huemul buck after being restrained with a rope at (a) approximately 2030 hours, (b) 14 h later, (c, d) bedded down, and (e) 15 h after having been roped. Dental root exposure and porous and recessed bone (f–h), deformation of the mandibula (i), disappearance of several teeth alveoli (j), and molars broken into several pieces or misaligned (k).



**Fig. 5.** Swelling on the left mandibular side of a huemul (a) before capture, (b) during immobilisation, and (c) later after her release.

individuals from this subpopulation were considered to have adequate Se concentrations (Chihuailaf *et al.* 2014), this was based on excluding from the analysis those samples with values below the detection limit. However, when all these values were included using the most conservative approach (e.g. Singh and Nocerino 2002), a reanalysis determined that at least 75% of the samples were indeed in the deficiency range (Flueck *et al.* 2014a). Taking this second analysis into account, relationships of various biological and ecological phenomena would need to be interpreted quite differently.

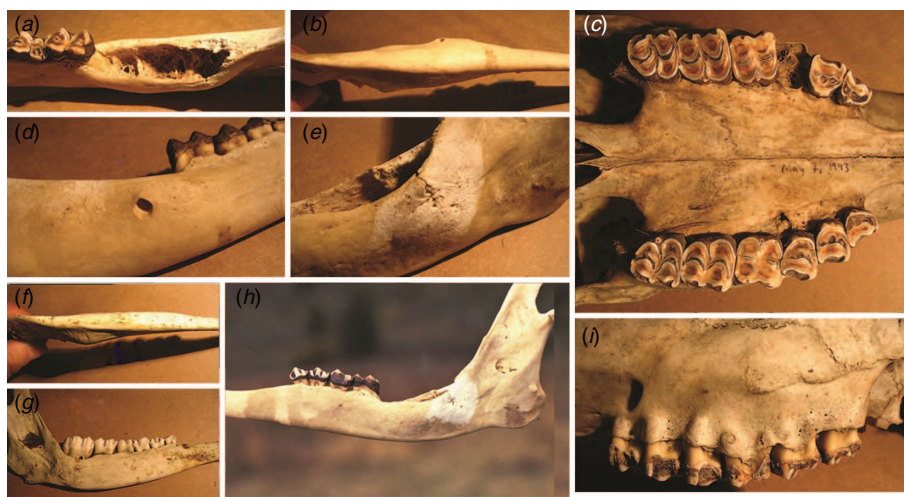
Moreover, this subpopulation was shown to have numerous cases of advanced osteopathology compatible with Se deficiency (Fig. 6; Flueck 2015). In an Argentine subpopulation, the prevalence of this osteological disease pattern has been shown to be at least 57% in the remains of dead adult huemul (Flueck and Smith-Flueck 2008), and 86% among the recently examined live adults (Flueck and Smith-Flueck 2017). Overall, this disease pattern has been documented in several subpopulations that are spread out along some 1000 km of the Andean mountain range (Fig. 1).

#### Case 6

Recently, the Chilean government was concerned about the possible presence of disease in huemul of Torres del Paine National Park (CONAF 2018). On 24 April 2018, a team of 13 specialists, including two veterinarians, was sent to Torres del Paine National Park for 4 days to evaluate whether such disease was the result of livestock presence, since the appearance of lesions was similar to that in the Cerro Castillo Reserve (CCR) further north, which was identified as caseous lymphadenitis (CLA) from *Corynebacterium pseudotuberculosis* (Morales *et al.* 2017).

However, not to be ignored are the intensive field studies conducted between 1999 and 2007 on this same population, where many cases of fawns and adults were documented to be affected by the same clinical symptoms (Fig. 7). These facts and photographic evidence were published in 2008, with the suggestion that some resemble the general disease of lumpy jaw (Guineo *et al.* 2008). Regardless, the presence of those lesions did not elicit any sanitary concerns or responses by health professionals for nearly two decades. Instead, the





**Fig. 6.** Examples of (a) extensive erosion of dental alveoli with missing teeth, (b, f) thickening of mandibular body, (c) erosions and perforation of the palate, (d) osteolytic lesion causing a large perforation, (e) pathological fracture, (g, h) bone resorption reducing mandibular height, and (i) pronounced porosification with large perforations exposing root apices.

present initiative was fuelled by the fact that CLA was diagnosed in huemul further north in the CCR. It is likely that CLA had been affecting huemul in this reserve long before the first case was documented by a local citizen, a lawyer and hobby photographer, in August 2014. His consistent documentation and reporting via the ‘Agrupación Cultural para la Protección del Huemul’ finally achieved a reaction from the public authorities in 2015 (de los Reyes Recabarren 2015), which then resulted in the identification of CLA by November 2015. Afflicted huemul individuals were then captured, treated and radio-collared.

First described in 1888 (Pepin and Paton 2010), CLA is a well known disease of global distribution. It was common in Argentina by 1913 (Dunlop Young 1934) and, notably, CLA was also recognised in Chile early on, such that it already became obligatory in the year of 1937 (Decreto No. 644) to report all cases to the government. Yet, the clinical cases documented in the Torres del Paine National Park since 1999 were never diagnosed, and those occurring in CCR were not confirmed until 2015 due to a private initiative.

The urgency and importance currently given to CLA in huemul is in stark contrast to the documented long existence of CLA in Chile and Argentina. Huemul, therefore, has been in contact with CLA for much of its existence in South America, due to it being in contact with species recognised as having been affected with CLA, namely sheep, goats, mules, horses, cattle, alpaca, other deer species, hares, and also native guanaco (Wernery and Kinne 2016). It is well known that cervids in other continents have also become infected, and infections in huemul are, thus, to be expected (Pepin and Paton 2010; Matos *et al.* 2015; Valli *et al.* 2016). Consequently, as the disease is not rare in wild species and does not indicate anything about the exact origin of CLA in wildlife, Pepin and Paton (2010), thus, suggested the need to differentiate sources according to contacts with domestic animals, or the existence of a wild fauna reservoir. Also, and being highly relevant, Se deficiency has been shown to negatively affect the antibody response in



**Fig. 7.** Examples of lesions in huemul from Torres del Paine National Park (Guineo *et al.* 2008).

sheep against CLA (Larsen *et al.* 1988). Last, a live huemul in CCR affected with CLA was also documented to have lost incisive teeth and misplacement of other teeth (D. Aldridge, pers. comm., 2018), which he considered equivalent to those cases described in Argentina by Flueck and Smith-Flueck (2008, 2017).

#### *Problematic risk assessments affecting conservation policy*

##### *Case 7*

In 1995, there was an initiative to establish the first rehabilitation and breeding centre for huemul in Argentina.

The proposal aimed to extend the then existing Centre of Wildlife Rehabilitation Shanti (Province of Chubut), by adding a Centre of Rehabilitation and Breeding for Huemul. However, according to received advice, establishment of the huemul centre was not allowed; the reasoning was that hardly any data on wild huemul existed, new field studies were to be launched, and, therefore, before more data were available, a new centre was, thus, not considered justifiable (Lizurume 1995).

A second initiative was launched in 2000 by researchers of the National Council of Scientific and Technological Research (Buenos Aires), again to establish the first rehabilitation and breeding centre for huemul, which would have relied on secured private funding for 30 years (Escobar Ruíz *et al.* 2017). As a first step, since neither the structure nor the size of any Argentine subpopulation had yet been determined, aerial census surveys of eight huemul subpopulations in unprotected areas were proposed and backed by funding already procured for the specific project. If it could, subsequently, be justified to extract two or three pairs of huemul from these subpopulations, the goal was then to start a centre (Flueck and Smith-Flueck 2006). However, the group leading the national huemul-conservation program (Regional Delegation for Patagonian National Parks) prevented the aerial surveys and, furthermore, advised the provincial authorities not to give a permit for a huemul centre (Ramilo 2001). Their assessment of risks, and resulting recommendations, were based on the following arguments:

- (1) the situation of huemul in Argentina has not yet reached the critical point that justifies the implementation of an *ex situ* program, with time yet remaining to prevent reaching such a state;
- (2) the risks associated with keeping huemul in captivity are, therefore, too high to take, as yet;
- (3) there are abundant areas containing huemul groups in a relatively good conservation state;
- (4) other activities have much higher conservation value than those obtained from *ex situ* programs;
- (5) current *in situ* efforts are sufficient to guarantee the long-term survival of huemul in Argentina and that, therefore, a conservation centre with semi-captive huemul is unnecessary;
- (6) previous attempts to keep huemul in captivity had failed;
- (7) modern techniques for wildlife research allow research on biological aspects essential for conservation without the need for studies conducted *ex situ*; and
- (8) no basic information, such as population structure, size or social system, is available, which would be necessary before animals can be extracted from a population.

Despite the strong reluctance of government authorities to accept a centre, a successful recovery would depend on understanding the main factors affecting individual subpopulations, and on well designed *in situ* and *ex situ* projects. Information gaps impeding conservation can be filled via research on semi-captive huemul, which would also provide animals for reintroductions or restocking. Accordingly, IUCN (2002) recommends, explicitly, that *ex situ* programs foster research on questions relevant for *in situ* conservation. Reintroductions using adaptive-management principles could determine factors presently preventing recovery (Walters and

Holling 1990). Successful diagnoses must be based on scientific monitoring (Sutherland 2000), which is notoriously lacking regarding huemul. In essence, no information has, yet, been generated on factors preventing recovery of any subpopulation (Flueck and Smith-Flueck 2006; Lopez Alfonsin 2019; Lopez Alfonsin and Sol Bucetto 2019). Suggesting that huemul has not yet reached the critical point justifying *ex situ* strategies counters the norms established by IUCN, who recommends such strategies while a species is still considered vulnerable and the number of individuals is still in the thousands (IUCN 1987). Notably, IUCN declared huemul to be at 'a very high risk of extinction' based on Category C2a, among others (IUCN 2001). Furthermore, the two asseverations by Ramilo (2001) that abundant areas contain huemul in a relatively good conservation state and that current *in situ* efforts are sufficient to guarantee the long-term survival of huemul both lack any foundation and do not agree with the documented situation. Then, the two claims that huemul in captivity is a risky undertaking and that previous attempts to keep huemul in captivity had failed are erroneous and ignore substantial literature documenting just the opposite. Several centres have successfully bred huemul as early as the 1930s (Smith-Flueck 2000; Smith-Flueck *et al.* 2004), and an extant centre has been successful for 15 years (reviewed in Escobar Ruíz *et al.* 2017). These recommendations that a conservation centre with semi-captive huemul would be too risky and unnecessary, and that *in situ* activities have a much higher conservation value, have prevented the formation of a centre, along with the consequential loss of many conservation benefits. It also reflects the application of terminology (*in situ* versus *ex situ*) in an outdated and obsolete way, disregarding the modern view of urgent metapopulation management in the anthropocene (Braverman 2014). It is well recognised that conservation centres contribute to a diverse array of *in situ* and *ex situ* conservation efforts, and serve as important partners with research and in the recovery of threatened species (Che-Castaldo *et al.* 2018; Lopez Alfonsin 2019; Lopez Alfonsin and Sol Bucetto 2019).

#### Case 8

Authorities of the Argentine province of Rio Negro denied a permit to capture and mark huemul on private land (2012), on the basis of the following arguments: (1) high risks from darting, capture and manipulations; (2) the precarious situation of the subpopulation with respect to applying such risky methods; and (3) availability of less invasive methods such as camera traps, surveys of tracks and other signs. A modified proposal was again denied in 2013, stating that the decision was based on the recommendations by the Committee of Scientific Advisors of the Argentine National Plan for Huemul Recovery. Once confirmed that several advisors had actually never been consulted (S. Di Martino and S. Gonzalez, pers. comm.), a persistent process to obtain access to government documentation finally resulted in a reply (Vinci 2016) which included an assessment of the only advisor that was consulted. The advice provided the following reasoning: (1) that the same recommendations had been provided in the previous assessment regarding a

similar proposal the year before; (2) that the proposal would first have to include a very strong justification for why the proposed captures were the only alternative to address the objectives; (3) that various objectives could be answered with non-invasive methods, such as using camera traps, instead of using extremely risky methods, such as darting; (4) that there must be an assigned veterinarian to take the responsibility for captures and drugs; and (5) recommended to consult with two Chilean veterinarians who had caught 49 and 20 deer respectively.

Even though the status of huemul has been considered endangered since 1973, Chile has proceeded to capture over 100 individuals since the 1980s. Meanwhile, not a single one had ever been marked in Argentina at the time of these proposals to the Rio Negro province (2012 and 2013). To suggest that chemical captures are extremely risky goes against their common practice worldwide, which is supported by clear risk analyses (Kock *et al.* 1987; DelGiudice *et al.* 2001). Insistence to have a veterinarian in charge is also not according to the law of most countries, including that of Argentina, and other certifications exist that permit non-veterinarians to handle wildlife. Moreover, suggesting that the proposal applicants need to consult the two recommended colleagues in Chile with capture experience could be argued against, given that the proposing scientists had already captured and marked over 250 other cervids, besides 15 huemul in Chile, and, in addition, had already obtained various capture permits for huemul from Argentine National Parks and other provinces.

Overall, there was no opportunity to defend or revise the proposal, given the province did not supply any material regarding their decision until several years later (Vinci 2016). Remarkably, that same year, another capture team received a permit backed by the Committee of Scientific Advisors of the Argentine National Plan for Huemul Recovery, and successfully radio-collared the first huemul in Argentina (APN 2016b). Their proposal aimed to capture only one huemul, explicitly as a means for them to gain initial experiences before additional future captures, and emphasised the importance of this first-ever capture operation (APN 2016a). Whereas darting was claimed to be extremely risky in response to the 2012 and 2013 proposals in the province Rio Negro, the 2016 proposal, in contrast, asserted the success of darting for capturing huemul in Chile, and, furthermore, attested that this method causes little stress to captured deer or to the rest of the population (APN 2016a). No additional huemul has since been marked there.

Thus, considering that the capture of only one huemul was later acceptable (APN 2016a), the earlier advice to Rio Negro province to deny the proposed capture project was inconsistent, especially given the experience of the proposal team in having captured 265 deer. Moreover, the decision of the committee based on the biased advice resulted in important losses of logistical arrangements, funding and time. Behind the earlier denial was the reasoning that a strong justification had to first be given for the need to dart and mark several huemul individuals as the only alternative for answering the objectives. Yet, similar objectives, namely, studying population dynamics, habitat use, seasonal movements, and interchange of huemul among subpopulations, were stated in

the 2016 proposal (APN 2016a), with emphasis given to telemetry methodology as a means to provide such information, and allowing to make conservation strategies in the national park more effective. Despite a sound intention by these project leaders, their questions will remain unanswered, given that only a single animal was radio-marked; then, further making the study design questionable, the radio functions for only 2 years or less. As a positive note, permits were eventually obtained by the team that was previously refused permits in another province, leading to successful capture and monitoring of six radio-collared huemul individuals in 2017. This operation required 97% less man/day efforts per animal than did the 2016 capture effort (Flueck and Smith-Flueck 2018).

Last, just 2 weeks before the planned 2016 capture operation, which resulted in the first marked huemul in Argentina, leading members of that same group were called to rescue a restrained huemul buck that had been tied to a fence post after an attempt to protect it from dogs (see Case 3 above). In summary, the rescuers arrived after a long delay and borrowing tranquilisers, and decided to still sedate the stressed buck 19 h post-capture. Notably, due to stress and lack of reversal, this young buck died 4 h later. Independently, the same group had authorised other researchers to capture and mark huemul, and were well aware that all elements for sedation as well as radio-collars for huemul were present at their facility. Regardless, in the case of the tied-up huemul buck, these researchers were not contacted despite being only 1 h away from the restrained buck. This string of decisions (Barbato 2016) leading to the death was followed by the eventual exhumation of the carcass of this unfortunate buck, so as to perform an essential necropsy, although it was done months after his death (Flueck 2018). If, instead, standard international protocols had been followed, a buck dying during the breeding season in the presence of a team of experts would have justified a myriad of analyses and tissue collections, particularly important for any species on the brink of extinction that lacks a substantial amount of pertinent data. For instance, in another case, after being advised of a fresh carcass of a radio-marked huemul buck in a remote area, the research team immediately travelled 700 km, performed a necropsy, and returned to process the material, resulting in varied valuable data and tissues, including viable gametes (Table 1).

## Conclusions

Given the severe predicament faced by the last few hundred and highly dispersed huemul individuals in Argentina, future prospects are primarily dependent on correct diagnoses of the basic factors preventing a population recovery, and on strategies to overcome these limiting factors. Such reduced numbers spread over large landscapes that are commonly difficult to access have impeded the creation of a well founded database. Consequently, every opportunity for an examination is highly valuable and should be used maximally. Repeated misdiagnoses of live and dead huemul cases have been observed, and this needs addressing.



**Table 1. List of postmortem tissue retrieval and other observations obtained from a huemul buck, 2018**

CT, computed tomography; MRI, magnetic resonance imaging

---

|  |
|--|
| Body fluid collections                                     |
| Blood (via cardiocentesis)                                 |
| Urine  |
| Viable sperm for cryopreservation                          |
| Lesions for microbe cultures                               |
| Samples for various determinations                         |
| Skin   |
| Hair   |
| Head and neck (MRI and CT scans)                           |
| Leg extremities with hooves                                |
| Skeleton   |
| Femur marrow   |
| Rumen contents   |
| Faecal pellets   |
| Fat content in bone marrow                                 |
| Fat deposit extent (omentum, rump, kidney, heart, sternum) |
| Weights (whole body, organs, digestive tract)              |
| Morphometry of body  |
| Morphometry of digestive tract                             |
| Samples for histology                                      |
| Lungs  |
| Kidney   |
| Spleen   |
| Liver  |
| Heart  |
| Muscle from different sites                                |
| Tongue   |
| Urinary bladder  |
| Testes   |
| Skin   |
| Rumen  |
| Abomasum   |
| Reticulum  |
| Leg joints   |
| Bone marrow  |
| Bone lesions   |
| Internal parasites   |

---

The fluorosis resulting from the 2008 Chaitén volcanic eruption had gone unnoticed (Fig. 8), similarly to the situation of the 2011 Puyehue eruption. Not only did these events affect wildlife (Flueck and Smith-Flueck 2013), including huemul (Izquierdo *et al.* 2018), but they also affected livestock (Flueck 2013). There is good consensus regarding measures aimed at reducing the toxic impact on animals, and livestock producers elsewhere have employed these successfully (Flueck 2016a, 2016b). In the case of huemuls being exposed to such toxicity, their critical conservation status would justify proactive management by keeping them in a rehabilitation centre, where young animals can be fed non-contaminated food at least during the development of their permanent teeth. This would result in the individuals gaining some extra years of life by slowing down the wear on healthy teeth. A second measure would be to provide supplemental nutrients as is practised in areas affected by excess fluorine. For instance, food containing ample amounts of calcium and vitamin C helps counteract fluorine toxicity (Ulemale *et al.*



**Fig. 8.** The eruption of the volcano Chaitén (1 May 2008) deposited a large amount of ash in the area of Cases 1 and 2 (see text). Ash deposits are still substantial in many areas.

2010; Choubisa 2015). Moreover, as fluorosis is aggravated by local iodine deficiency, which increases the incidence and harshness of fluorosis (Matamoros *et al.* 2003), and by local deficiency of Se, which among other things also results in secondary deficiency of iodine, these nutrients could also be supplemented if shown to be deficient.

The misdiagnoses of cases with overt osteopathology is striking. Such individuals certainly should not be released back to the wild where their life span would be extremely reduced. Additionally, it would result in much unnecessary suffering; exactly this occurred with a buck that was radio-marked in mid-winter 2017. He had already lost seven of the eight incisive teeth and was emaciated (Flueck and Smith-Flueck 2017). Although he did survive that winter, he succumbed during the following winter. He had also lost maxillary premolars and exhibited several severe cranial bone lesions. Given that there were no body fat reserves, that bone marrow was down to 15% fat, and that no other lesions were present, starvation was indicated as the cause of death (W. T. Flueck and J. M. Smith-Flueck, unpubl. data). Instead, by extending life under controlled *ex situ* conditions, such debilitated animals could still be able to contribute to the population genetically and numerically, by continuing to produce offspring.

Moreover, the high prevalence of osteopathology among adults has been well documented (Flueck and Smith-Flueck 2008), with at least 57% of dead adult huemuls being affected, and, of those, 100% and 78% had cranial and appendicular lesions respectively. This pattern was confirmed *in vivo* where 86% of examined adults had lesions (Flueck and Smith-Flueck 2017). Furthermore, this disease pattern has been documented in subpopulations spread along some 1000 km of the Andean mountains (e.g. Texera 1974). The link to nutritional ecology, particularly to deficiency of trace elements, has been suggested repeatedly (Flueck and Smith-Flueck 2008, 2011; Flueck *et al.* 2012, 2014a), and has been, subsequently, supported by several studies, including the following: (1) Se deficiency was shown in a population with osteopathology (Flueck

2015); (2) soil Se concentrations were shown to be at the low end of the range considered deficient (Flueck *et al.* 2014b); and (3) hair analysis of 18 individuals indicated trace-element deficiencies (W. T. Flueck, J. M. Smith-Flueck and L. H. Winkel, unpubl. data). These observations are further accompanied by numerous reports of live huemul being found with broken bones (Cerda *et al.* 2011), another phenomenon that has not been described in other cervid species, and may be related to nutritional deficiencies, including that of Se (Pilarczyk *et al.* 2013). Given such published antecedents covering nearly 20 years, *in vivo* examinations of huemul undoubtedly must emphasise relevant diagnostic approaches addressing the hitherto described pathophysiology.

Reducing diagnostic errors is an important goal because of the associated morbidity and potential preventability (Croskerry 2003). Aftermaths of failed diagnosis include a reduced life expectancy, when the alternative could be to take a debilitated individual to a rehabilitation centre. Furthermore, at the current precarious state of this species, individuals under controlled conditions can provide useful opportunities to answer numerous pending research questions. These repeated cases of diagnostic errors reported here are non-trivial, given the few rare opportunities to evaluate live or fresh specimens of this highly endangered species. Professionals frequently underappreciate the likelihood that their diagnoses are wrong, and this tendency to be overconfident is related to both intrinsic (e.g. cognitive errors) and systemically reinforced factors (Berner and Graber 2008). Additionally confirming *in vivo* diagnoses via postmortem analyses is an essential approach to measure the incidence of the diagnostic error. Such errors are common also in human medicine, and even regarding common diseases that are mislabelled or missed entirely (Graber 2013).

Aside from actual misdiagnoses on live and dead huemul individuals, there are also conceptual ones that can seriously impair progress in conservation measures. Thus, erroneous assessments of methodological risks, or unfounded confidence in a supposedly adequate conservation state, have prevented, in Argentina, the establishment of captive centres (1995, 2000) and the use of helicopters and captures in general. The Argentine system for huemul operates under a centralised advisory board at the federal level, which is controlled by a restricted group and lacks transparency (Lopez Alfonsin 2019; Lopez Alfonsin and Sol Bucetto 2019). Only recently have local authorities opted to make independent decisions, which allowed, for one, the capturing of huemul so as to conduct the first telemetry study of a huemul group, and also the initiation of the first breeding and rehabilitation centre for huemul, despite uninvited advice from members of the national advisory board to not permit establishment of such a centre. If this centre will be as successful as the only one currently existing, Huilo Huilo in Chile (Vidal *et al.* 2018), the first reintroductions will be conducted in historical winter ranges under an adaptive-management approach.

### Conflicts of interest

The authors declare no conflicts of interest.

### Acknowledgements

We thank the many colleagues who, over the years, have assisted with field work and with the interpretation of data. We also thank the two reviewers for their well thought suggestions. We also thank the organisers of the 9th International Deer Biology Congress (5–10 August 2018 at the YMCA of the Rockies in Estes Park, Colorado), where this paper was presented. This research did not receive any specific funding.

### References

- Administración de Parques Nacionales Argentina (APN) (2016a) DRP: captura de huemules para su seguimiento por telemetría – programa Conservación del Huemul APN. (Ed. E Ramilo) Report CUDAP TRI-PNA:0000671/2016. APN, Buenos Aires, Argentina.
- Administración de Parques Nacionales Argentina (APN) (2016b) ‘En la senda del huemul.’ Available at [www.parquesnacionales.gov.ar/2016/04/en-la-senda-del-huemul](http://www.parquesnacionales.gov.ar/2016/04/en-la-senda-del-huemul) [Verified 4 April 2016]
- Aitken ID (2007) ‘Diseases of sheep.’ 4th edn. (John Wiley & Sons: Chichester, UK)
- Barbato LC (2016) Denuncia sobre muerte de huemul. In ‘Resolución PD 126/2016, Administración de Parques Nacionales’. (Eds Oficina de sumarios e investigaciones administrativas) pp. 1–382. (Administración de Parques Nacionales: Buenos Aires, Argentina)
- Berner ES, Graber ML (2008) Overconfidence as a cause of diagnostic error in medicine. *The American Journal of Medicine* **121**, S2–S23. doi:10.1016/j.amjmed.2008.01.001
- Braverman I (2014) Conservation without nature: the trouble with *in situ* versus *ex situ* conservation. *Geoforum* **51**, 47–57. doi:10.1016/j.geoforum.2013.09.018
- Cerda J, Llanos A, Vidal F (2011) Surgical amputation of foreleg in South Andean deer (huemul, *Hippocamelus bisulcus*) in Coyhaique, Chile. *Animal Production Science* **51**, li–liv.
- Chang Reissig E, Quiroga A, Massone A, Gimeno E, Pastore H, Ramilo E, Izquierdo M, Corvalán F, Lizardo V, Ielpi C, Uzal FA (2015) Possible intoxicación por *Astragalus* sp. en un huemul *Hippocamelus bisulcus*. In ‘IX seminario Argentino Fundación Charles Louis Davis and VII reunión del Forum Permanente en Enseñanza de Patología Veterinaria’. (Universidad Católica de Salta: Salta, Argentina) Available at [www.conicet.gov.ar/new\\_scp/detalle.php?keywords=&id=32614&](http://www.conicet.gov.ar/new_scp/detalle.php?keywords=&id=32614&) [Verified January 2020]
- Che-Castaldo JP, Grow SA, Faust LJ (2018) Evaluating the contribution of North American zoos and aquariums to endangered species recovery. *Scientific Reports* **8**, 9789.
- Chehebar C (2016) Participación de personal de la Delegación Regional Patagonia en el intento de rescate y liberación de un ejemplar de huemul en la localidad El Manso, Provincia de Río Negro. In ‘Denuncia sobre muerte de huemul, Resolución PD 126/2016, Administración de Parques Nacionales’. (Ed. LC Barbato) pp. 60–64. (Administración de Parques Nacionales: Buenos Aires, Argentina)
- Chihuailaf RH, Stevenson VB, Saucedo C, Corti P (2014) Blood mineral concentrations in the endangered huemul deer (*Hippocamelus bisulcus*) from Chilean Patagonia. *Journal of Wildlife Diseases* **50**, 146–149. doi:10.7589/2013-03-063
- Choubisa AL (2015) Industrial fluorosis in domestic goats (*Capra hircus*), Rajasthan, India. *Fluoride* **48**, 105–112.
- CONAF (2018) ‘CONAF preocupada por posible presencia de enfermedad en huemules de Torres del Paine.’ Available at [www.conaf.cl](http://www.conaf.cl) [Verified 26 April 2018]
- Croskerry P (2003) The importance of cognitive errors in diagnosis and strategies to minimize them. *Academic Medicine* **78**, 775–780. doi:10.1097/00001888-200308000-00003
- Davis JW, Anderson RC (1971) ‘Parasitic diseases of wild mammals.’ 1st edn. (Iowa State University Press: Ames, IA, USA)



- Davis JW, Karstad LH, Trainer DO (1981) 'Infectious diseases of wild mammals.' 2nd edn. (Iowa State University Press: Ames, IA, USA)
- de los Reyes Recabarren R (2015) '*Hippocamelus bisulcus*: equivocaciones desde el inicio. El Divisadero.' Available at [www.eldivisadero.cl](http://www.eldivisadero.cl) [Verified January 2020]
- DelGiudice GD, Mangipane BA, Sampson BA, Kochanny CO (2001) Chemical immobilization, body temperature, and post-release mortality of white-tailed deer captured by clover trap and net-gun. *Wildlife Society Bulletin* **29**, 1147–1157.
- Dunlop Young T (1934) Caseous lymphadenitis; pseudo-tuberculosis of sheep; cheesy broncho-pneumonia. *Veterinary Journal* **90**, 407–409.
- Escobar Ruíz EM, Gizejewski Z, Hoby S, Flueck WT, Smith-Flueck JM (2017) El valor de los centros de conservación para la supervivencia del huemul. Chapter 12. In 'El Huemul de Aysén y otros rincones'. (Eds A Iriarte, DS Donoso, B Segura, M Tirado) pp. 198–215. (Ediciones Secretaría Regional Ministerial de Agricultura de la Región de Aysén y Flora & Fauna Chile Ltd: Aysen, Chile)
- Flueck WT (2013) Effects of fluoride intoxication on teeth of livestock due to a recent volcanic eruption in Patagonia, Argentina. *Online Journal of Veterinary Research* **17**, 167–176.
- Flueck WT (2015) Osteopathology and selenium deficiency co-occurring in a population of endangered Patagonian huemul (*Hippocamelus bisulcus*). *BMC Research Notes* **8**, 330. doi:10.1186/s13104-015-1291-9
- Flueck WT (2016a) The impact of recent volcanic ash depositions on herbivores in Patagonia: a review. *The Rangeland Journal* **38**, 27–34. doi:10.1071/RJ14124
- Flueck WT (2016b) Extended chronology of the Córdón Caulle volcanic eruption beyond 2011 reveals toxic impacts. *Natural Hazards and Earth System Sciences* **16**, 2351–2355. doi:10.5194/nhess-16-2351-2016
- Flueck WT (2018) Elusive cranial lesions severely afflicting young endangered Patagonian huemul deer: a case report. *BMC Research Notes* **11**, 638. doi:10.1186/s13104-018-3755-1
- Flueck WT, Smith-Flueck JM (2006) Predicaments of endangered huemul deer, *Hippocamelus bisulcus*, in Argentina: a review. *European Journal of Wildlife Research* **52**, 69–80. doi:10.1007/s10344-005-0020-4
- Flueck WT, Smith-Flueck JM (2008) Age-independent osteopathology in skeletons of a south American cervid, the Patagonian huemul (*Hippocamelus bisulcus*). *Journal of Wildlife Diseases* **44**, 636–648. doi:10.7589/0090-3558-44.3.636
- Flueck WT, Smith-Flueck JM (2011) Recent advances in the nutritional ecology of the Patagonian huemul: implications for recovery. *Animal Production Science* **51**, 311–326. doi:10.1071/AN10237
- Flueck WT, Smith-Flueck JM (2013) Severe dental fluorosis in juvenile deer linked to a recent volcanic eruption in Patagonia. *Journal of Wildlife Diseases* **49**, 355–366. doi:10.7589/2012-11-272
- Flueck WT, Smith-Flueck JM (2017) Troubling disease syndrome in endangered live Patagonian huemul deer (*Hippocamelus bisulcus*) from the Protected Park Shoonem: unusually high prevalence of osteopathology. *BMC Research Notes* **10**, 739. doi:10.1186/s13104-017-3052-4
- Flueck WT, Smith-Flueck JM (2018) Radio marking the first group of endangered Patagonian huemul deer in Argentina. *Journal of Neotropical Mammalogy* **25**, 461–465. doi:10.31687/saremMN.18.25.2.0.07
- Flueck WT, Smith-Flueck JM, Mionczynski J, Mincher BJ (2012) The implications of selenium deficiency for wild herbivore conservation, a review. *European Journal of Wildlife Research* **58**, 761–780. doi:10.1007/s10344-012-0645-z
- Flueck WT, Smith-Flueck JM, Mincher BJ, Winkel LHE (2014a) An alternative interpretation of plasma selenium data from endangered Patagonian huemul deer (*Hippocamelus bisulcus*). *Journal of Wildlife Diseases* **50**, 1003–1004. doi:10.7589/2014-03-077
- Flueck WT, Smith-Flueck JM, Mincher BJ, Winkel LHE (2014b) Soil selenium levels corroborate direct evidence of selenium deficiency in endangered Patagonian huemul deer (*Hippocamelus bisulcus*). In 'Proceedings of the 8th international deer biology congress'. (Eds J Ma, M Zhang, R Halbrook, B Liu, W Zhang) pp. 52–53. (Northeast Forestry University: Harbin, China)
- Graber ML (2013) The incidence of diagnostic error in medicine. *BMJ Quality & Safety* **22**, ii21–ii27. doi:10.1136/bmjqs-2012-001615
- Grandjean P, Landrigan PJ (2014) Neurobehavioral effects of developmental toxicity. *Lancet Neurology* **13**, 330–338. doi:10.1016/S1474-4422(13)70278-3
- Guíneo O, Guíneo Garay R, Garay G (2008) 'Conociendo al huemul de Torres del Paine.' (La Prensa Austral: Punta Arenas, Chile)
- Hebert DM, Cowan IM (1971) White muscle disease in the mountain goat. *The Journal of Wildlife Management* **35**, 752–756. doi:10.2307/3799782
- IUCN (1987) 'The IUCN policy statement on captive breeding. No. IUCN-PP-001.' (IUCN: Gland, Switzerland)
- IUCN (2001) 'IUCN red list categories, version 3.1.' (IUCN Species Survival Commission: Gland, Switzerland)
- IUCN (2002) 'IUCN technical guidelines on the management of *ex-situ* populations for conservation.' (IUCN: Gland, Switzerland)
- Izquierdo VM, Flueck WT, Smith-Flueck JM, Bauer G (2018) Fluorosis confirmed in an endangered Patagonian huemul deer population resulting from a 2008 volcanic eruption. In '9th international deer biology congress'. (Estes Park, CO, USA)
- Jones TC, Hunt RD, King NW (1997) 'Veterinary pathology.' 6th edn. (Williams & Wilkins: Baltimore, MD, USA)
- Kock MD, Jessup DA, Clark RK, Franti CE, Weaver RA (1987) Capture methods in five subspecies of free-ranging Bighorn sheep: an evaluation of drop-net, drive-net, chemical immobilization and the net-gun. *Journal of Wildlife Diseases* **23**, 634–640. doi:10.7589/0090-3558-23.4.634
- Larsen HJ, Moksnes K, Overnes G (1988) Influence of selenium on antibody production in sheep. *Research in Veterinary Science* **45**, 4–10. doi:10.1016/S0034-5288(18)30886-5
- Lizurume JL (1995) 'Centro de rehabilitación y cria de huemul.' Nota 328 de 30 Ago. (Ministerio de Gobierno, Trabajo y Justicia: Rawson, Provincia de Chubut, Argentina)
- Lopez Alfonsín MA (2019) La protección del huemul como monumento natural, una asignatura pendiente de decisión política. *Revista Iberoamericana de Derecho Ambiental y Recursos Naturales* **34**,
- Lopez Alfonsín MA, Sol Bucetto M (2019) Endangered species and mechanisms for the recovery and conservation of biodiversity: a study on the viability of mechanisms and bureaucratic obstacles. *LEX* **17**, 297–324. doi:10.21503/lex.v17i23.1680
- Martínez A, Robles C, Gimeno E (2014) Intoxicación por garbancillo o yerba loca. *Presencia* **62**, 5–8.
- Matamoros R, Contreras PA, Wittwer F, Mayorga MI (2003) Hypothyroidism in ruminants. *Archivos de Medicina Veterinaria* **35**, 1–11.
- Matos AC, Dias AP, Morais M, Figueira L, Martins MH, Matos M, Pinto ML, Coelho AC (2015) Granuloma coinfection with *Mycobacterium bovis*, *Mycobacterium avium* subsp. *paratuberculosis*, and *Corynebacterium pseudotuberculosis* in five hunted red deer (*Cervus elaphus*) in Portugal. *Journal of Wildlife Diseases* **51**, 793–794. doi:10.7589/2014-09-240
- Morales N, Aldridge D, Bahamonde A, Cerda J, Araya C, Muñoz R, Saldías ME, Lecocq C, Fresno M, Abalos P, Retamal P (2017) *Corynebacterium pseudotuberculosis* infection in Patagonian Huemul (*Hippocamelus bisulcus*). *Journal of Wildlife Diseases* **53**, 621–624. doi:10.7589/2016-09-213
- Pepin M, Paton MW (2010) Caseous lymphadenitis in sheep and goats. Chapter 86. In 'Infectious and parasitic diseases of livestock'. (Eds PC Lefevre, J Blancou, R Chermette, G Uilenberg) pp. 1151–1163. (Lavoisier: Cachan Cedex, France)

- Pilarczyk B, Tomza-Marciniak A, Pilarczyk R, Bkowska M, Gaik M, Wilk M, Kuba J (2013) Relationship between serum Se concentration in dogs and incidence of some disease conditions. *Central European Journal of Biology* **8**, 527–533.
- Ramilo E (2001) Cría en cautiverio del huemul, consideraciones generales: Delegación Regional Patagonia, Administración de Parques Nacionales, Argentina. In 'Expediente Proyecto de censos poblacionales de huemul en el invierno en la provincia de Chubut'. (Ed. Dirección de Fauna y Flora Silvestres) pp. 17–19. (Escribanía General de Gobierno: Rawson, Provincia de Chubut, Argentina)
- Robles CA, Saber C, Jeffrey M (2000) Intoxicación por *Astragalus pehuénches* (locoísmo) en ovinos Merino de la Patagonia Argentina. *Revista de Medicina Veterinaria* **81**, 380–384.
- Salwasser H, Jessup D (1978) A methodology for performing necropsies and data analysis on road-killed deer. California Department of Fish and Game internal report. California Department of Fish and Game, Sacramento, CA, USA.
- Singh A, Nocerino J (2002) Robust estimation of mean and variance using environmental data sets with below detection limit observations. *Chemometrics and Intelligent Laboratory Systems* **60**, 69–86. doi:10.1016/S0169-7439(01)00186-1
- Smith-Flueck JM (2000) The Current Situation of the Patagonian huemul. Chapter 4. In 'The Patagonian huemul: a mysterious deer on the brink of extinction'. (Eds NI Díaz, JM Smith-Flueck) pp. 67–146. (LOLA: Buenos Aires, Argentina)
- Smith-Flueck JM, Díaz NI, Flueck WT (2004) Cría de huemules en cautiverio: las perspectivas actuales considerando las experiencias históricas. Chapter. In 'Cría en cautividad de fauna Chilena'. (Eds A Iriarte, C Tala, B Gonzalez, B Zapata, G Gonzalez, M Maino) pp. 457–470. (Servicio Agrícola y Ganadero – Parque Metropolitano, Zoológico Nacional, Universidad de Chile: Santiago, Chile)
- Stegelmeyer BL, James LF, Gardner DR, Panter KE, Lee ST, Ralphs MH, Pfister JA, Spraker TR (2005) Locoweed (*Oxytropis sericea*): induced lesions in mule deer (*Odocoileus hemionus*). *Veterinary Pathology* **42**, 566–578. doi:10.1354/vp.42-5-566
- Sutherland WJ (2000) 'The conservation handbook: research, management and policy.' (Blackwell Science: Berlin, Germany)
- Texera WA (1974) Algunos aspectos de la biología del huemul (*Hippocamelus bisulcus*) (Mammalia: Artiodactyla, Cervidae) en cautividad. *Anales del Instituto de la Patagonia, Punta Arenas (Chile)* **5**, 155–188.
- Ulemale AH, Kulkarni MD, Yadav GB, Samant SR, Komatwar SJ, Khanvilkar AV (2010) Fluorosis in cattle. *Veterinary World* **3**, 526–527.
- Valli VEO, Kiupel M, Bienzle D, Wood D (2016) Hematopoietic system. Chapter 2. In 'Jubb, Kennedy & Palmer's pathology of domestic animals, vol. 3'. (Ed. M Grant Maxie) pp. 102–268. (Saunders Elsevier: Philadelphia, PA, USA)
- Vidal F, Arias E, Garrido F, Parra Y, Espinoza J (2018) Experimental reintroduction of South Andean huemul and guanaco in the Huilo Huilo Chilean Private Reserve, Chile. In 'Global reintroduction perspectives: case studies from around the globe'. (Ed. PS Soorae) pp. 125–129. (IUCN/SSC Reintroduction Specialist Group: Gland, Switzerland)
- Vinci MC (2016) Observaciones sobre el proyecto 'Huemul en peligro: propuesta de un manejo adaptativo'. Assessment report by M Uhart to the Director of Wildlife, Nota SAyDS No. 588/2016. Secretaría de Ambiente y Desarrollo Sustentable, Viedma, Rio Negro, Argentina.
- Walters CJ, Holling CS (1990) Large-scale management experiments and learning by doing. *Ecology* **71**, 2060–2068. doi:10.2307/1938620
- Wernery U, Kinne J (2016) Caseous lymphadenitis (pseudotuberculosis) in camelids: a review. *Austin Journal of Veterinary Science & Animal Husbandry* **3**, 1022
- Wobeser GA, Spraker TR (1980) Post-mortem examination. In 'Wildlife management techniques manual'. (Ed. SD Schemnitz) pp. 89–98. (The Wildlife Society: Washington, DC, USA)

Handling editor: Gordon Dryden